

Case Report

Ringozone: The Slaughterhouse of Atopic Dermatitis

¹Khalse B, ²Ghule S, ³Lad D, ⁴Phatke S, ⁵Khadke J, ⁶Shivarkar P, ⁷Darade G

^{1,2,3,4,5,6}Department of Microbiology, Jayawantrao Sawant College of Commerce and Science, Hadapsar, Pune, Maharashtra, India.

⁷Department of Library, Jayawantrao Sawant College of Commerce and Science, Hadapsar, Pune, Maharashtra, India.

Article Info

Article history:

Received: October 18, 2022

Accepted: November 5, 2022

Published: November 10, 2022

Corresponding Author: Darade G, Email: ganeshdarade13069@gmail.com

© Author(s). This work is licensed under a [Creative Commons Attribution-NonCommercial-ShareAlike 4.0 International License](https://creativecommons.org/licenses/by-nc-sa/4.0/) that permits noncommercial use of the work provided that credit must be given to the creator and adaptation must be shared under the same terms.

Atopic dermatitis is found everywhere and it is a long lasting, inflammatory as well as relapsing disease of the skin [1]. The term atopic dermatitis is used synonymously with the term eczema (acute manifestation by the disease) [1]. Skin dermatitis is a major health problem in the world with varying degrees [2]. It is a chronic infection that infects lower part of neck (figure 1), face, head [1], scalp (figure 2a, 2b), foot [1] (figure 5), pelvic regions, nails, thighs (figure 3a, 3b, 4). A 35 years old male patient had this health issue from 2008 [1] (in contrast to H. C. Williams, (2005) [3], who proposed that the disease in question affects the patients with the ages below five years. He had a chronic dermatitis with round shaped growing zone of atopic dermatitis (figure 5), redness of skin, ring shaped skin damage in growing fashion, and intermittent itching.

Eczema can be severely complicated by viruses, bacteria as well as fungi resulting into superinfections [1]. However, the patient didn't try to prevent the disease by lowering the dryness of the skin and not using emollients as he was not aware about it in contrast to the recommendation by Thomsen SF et al. (2014) [1] who stated that lowering dryness of the skin helps in the eczema prevention.

The patient didn't use topical corticosteroids for the treatment as per recommendation by Thomsen SF et al. (2014) [1] and Calcineurin Inhibitors suggested by M.M.Y. El-Batawy, (2009) [5]. He took medicines (appendix 1) which were never proved to be useful.

Table 1: Pack size, manufacturer, composition and the disease getting treated in relation with Ringozone [4].

Pack size	13 gms
Manufacturer	Ringazone Ointment
Composition	Salicylic acid and Dithranol
Treatment	Eczema

Then, he moved to a Ringozone, a lotion that is available with very less price (Indian rupees 30/- only) containing Salicylic acid and Dithranol (table 1; appendix 1). He observed that the results were good (figure 6a, 6b). We conclude that the medicines which he used were ineffective because the resistance developed in the pathogens against them and there is a need to have the broad research operations in this regard across globe. However, in the current era, the Ringozone ointment is the best to treat the atopic dermatitis.

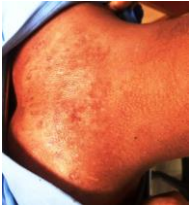


Figure 1: Fungal infection on bottom side of a neck.

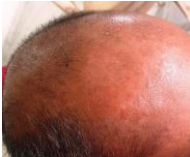

Figure 2a: Fungal infection of scalp

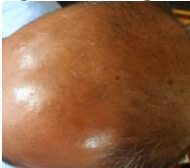

Figure 2b: Fungal infection of scalp

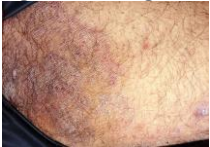


Figure 3a: Fungal infection of upper part of the thigh region.

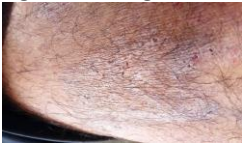

Figure 3b: Fungal infection of a thigh region.

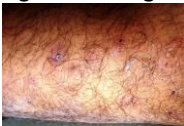

Figure 4: Fungal infection on thigh region

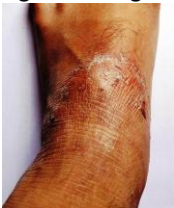

Figure 5: Fungal infection of the dorsal part of a foot.

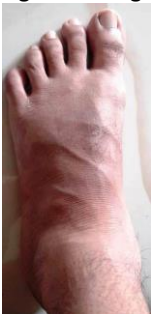

Figure 6a: Dorsal view of a foot after treatment.

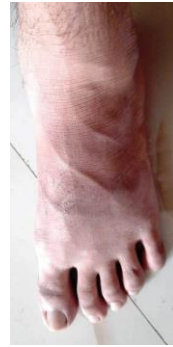

Figure 6b: Dorsal view of a foot after treatment.

Author contributions: GD: Developed an idea. BK, SG, DL, SP, JK, PS: Wrote the manuscript.

Competing interest: Authors declare that no conflict of interest exists.

Ethical Statement: This work has been performed with official permission of the patient under study.

Grant Support Details: Authors did not get funding from any agency to complete this work.

Acknowledgement: Authors are thankful to Rajesh Dhakane, Assistant Professor, Department of Microbiology, Jayawantrao Sawant Commerce and Science College, Hadapsar, Pune, Maharashtra, India to support completion of this work.

References:

1. Thomsen SF. Atopic dermatitis: natural history, diagnosis, and treatment. *ISRN Allergy*. 2014 Apr 2;2014:354250. doi: [10.1155/2014/354250](https://doi.org/10.1155/2014/354250), PMID [25006501](https://pubmed.ncbi.nlm.nih.gov/25006501/). PMCID [PMC4004110](https://pubmed.ncbi.nlm.nih.gov/PMC4004110/).
2. Asher MI, Montefort S, Björkstén B, Lai CK, Strachan DP, Weiland SK et al. Worldwide time trends in the prevalence of symptoms of asthma, allergic rhinoconjunctivitis, and eczema in childhood: ISAAC Phases One and Three repeat multicountry cross-sectional surveys. *Lancet*. 2006;368(9537):733-43. doi: [10.1016/S0140-6736\(06\)69283-0](https://doi.org/10.1016/S0140-6736(06)69283-0), PMID [16935684](https://pubmed.ncbi.nlm.nih.gov/16935684/).
3. Williams HC. Clinical practice. Atopic dermatitis. *N Engl J Med*. 2005;352(22):2314-24. doi: [10.1056/NEJMc042803](https://doi.org/10.1056/NEJMc042803), PMID [15930422](https://pubmed.ncbi.nlm.nih.gov/15930422/).
4. India mart. Available from: <https://www.indiamart.com/proddetail/ringozone-oointment-20440499173.html>.
5. El-Batawy MMY, Bosseila MA-W, Mashaly HM, Hafez VSGA. Topical calcineurin inhibitors in atopic dermatitis: a systematic review and meta-analysis. *J Dermatol Sci*. 2009;54(2):76-87. doi: [10.1016/j.jdermsci.2009.02.002](https://doi.org/10.1016/j.jdermsci.2009.02.002), PMID [19303745](https://pubmed.ncbi.nlm.nih.gov/19303745/).

Cite this article as: Khalse B, Ghule S, Lad D, Phatke S, Khadke J, Shivarkar P, Darade G. Ringozone: The slaughterhouse of atopic dermatitis. *Int. J. Micro. Sci*. 2022;3(1):50-52.

Appendix 1

Sequence of events:

Sr. no.	Date	Event	Medicine	Effect
1	1 September 2008	Atopic dermatitis occurred in the groin region	Clobate GM cream	Temporary
2	10 July 2017	Atopic dermatitis infection re-emerged	Clobate GM cream	Temporary
3	2 February 2020	Atopic dermatitis re-emerged	Clotrimazole dusting powder (antifungal, antibacterial)	Temporary
4	18 June 2020	Atopic dermatitis re-emerged	1. Candid-B (Clotrimazole and Beclomethasone) 2. Quadri Derm RF Cream	Weak recovery
5	8 October 2020	Atopic dermatitis re-emerged	Luliconaz Cream	Weak recovery
6	5 March 2022	Atopic dermatitis re-emerged	1. Benzoic acid with salicylic acid ointment 2. Amorolfine Cream 0.25% w/v 3. Itraconazole Capsule BP-50 mg 4. Foristal	Weak recovery
7	16 September 2022	Atopic dermatitis re-emerged	Dermifold Cream	No effect
8	6 October 2022	Atopic dermatitis re-emerged	Candid dusting powder	No Effect
9	8 October 2022	The foot of patient was treated by lotion	Ringozone	Mild Recovery
10	15 October 2022	Patient continued application of a lotion	Ringozone	Strong recovery
11	18 October 2022	Patient continued application of a lotion	Ringozone	Atopic dermatitis successfully treated (figure 6a, 6b).