

Case Report

Young patient's chronic fever

¹Murarkar K, ²Mankar S, ³Warthi S, ⁴Kapse Y, ⁵Kataria K, ⁶Moon J, ⁷Ganvir K

^{1,2,3,4,7}Department of Microbiology, Dr.R.G. Bhojar Arts Commerce and Science (Vidyabharti) College, Seloo, Wardha, Maharashtra, India.

⁵Katariya Hospital, Hinganghat, Maharashtra, India.

⁶Dr. Jaychand Moon Hospital, Wardha, Maharashtra, India.

Article Info

Article history:

Received: May 10, 2022

Accepted: June 10, 2022

Published: June 17, 2022

Corresponding Author: Kshama Murarkar, Email: kmurarkar@gmail.com

©Author(s). This work is licensed under a [Creative Commons Attribution-NonCommercial-ShareAlike 4.0 International License](https://creativecommons.org/licenses/by-nc-sa/4.0/) that permits noncommercial use of the work provided that credit must be given to the creator and adaptation must be shared under the

Typhoid fever is an infectious serious infection marked by intestinal inflammation and ulceration. This is an important public health problem in developing countries caused by the bacterium *Salmonella typhimurium* and *Salmonella paratyphi* [1]. First, bacteria enter the intestinal tissue without symptoms for 2 weeks. Then, these, soon invade the bloodstream, often taking 10 days and causing a high fever. Finally, the bacteria are localized in the gallbladder and surrounding organs and cause lesions. The major symptoms of typhoid are fever, rash, weakness, abdominal pain, constipation, and headaches. Typhoid fever is particularly high; gradually increasing over several days up to 39 to 40 °C. Now, it's a typical appearance is seen in the tropics. In this case report, a case of 21 years male suffered from typhoid fever has been reported.

A twenty-one years old male student in B.Sc. final year from Taluka Girad (Samudrapur), District Wardha, Maharashtra, India came to the Wardha district to complete his Diploma course in Medical Laboratory Technology in 2018. At that time, his health was good in condition. After near about one and half years, he

suffered from mild fever for up to 4-5 months. He went to Dr. Jaychand Moon, Medical Officer and family physician in Wardha for treatment. The doctor prescribed Cefuroxime and cough medicines and some blood tests. The fees of the doctor were not affordable to the patient, so he avoided taking the medical test. The medication from the doctor felt him better. Nevertheless, he did not visit the doctor again due to financial problems. In May 2020, he suffered from high fever during the fifth semester of his Diploma examination. He didn't take any advice from a medical practitioner and used to take paracetamol without concerning the doctor to recover from the fever. This antipyretic drug helped him feel better but not completely recovered him.

He ignored the mild fever during that period and avoided visiting the physiologist. After seven months, he went to his hometown in June 2020 due to the Covid-19 lockdown in India. During that time, he started to work on his farmland to help his parents, and once he drank well water. And again, his health started to deteriorating. For about 10 days, he took home remedies using Ayurvedic medicines

Paripathadikadha and Amrutrishta without concerning the doctor. Shockingly, there was no improvement in his health. After ten days, he visited the hospital. According to the doctor's (name not disclosed) preliminary examination, the fever could be viral or malarial. The doctor prescribed drugs Laringo DS, Amoxicillin, and Deriphyline which made the patient to feel better. In contrast, after 4 to 5 hours, high fever was reported. This fever condition continued up to one month. During this situation, he lost his appetite and got weakness, and he was unable to stand properly. He had the experience of dizziness. He had given up hope of survival. Later, he went to another doctor in Katariya hospital, Hinganghat, Maharashtra, India. He proceeded through a Complete Blood Count (CBC) test, urine test, and Widal test, in which the Widal test showed a positive report. He was diagnosed with *S. typhi*. During this period, he lost weight up to 7 kg. He was treated for typhoid fever and recovered. After recovery, he performed biochemical tests and CBC tests. Typhoid fever disappeared completely within 3 weeks.

Since 2020, the frequent mild fever (reasons unknown) up to 4-5 months and high fever during his examination was reported. Due to unawareness and ignorance of health and self-medication, the fever was not completely recovered because the infection persisted. In addition, during the lockdown period, he started working on farms and also took the well water. The reason for his ill health might be earlier typhoid infection. During the lockdown period, the unavailability of doctors and the use of self-

medications, home remedies, and Ayurvedic treatment without knowing the real cause increased typhoid infection. There is a need to take treatment for typhoid to avoid health crisis.

Authors' Contributions: KM: Developed an idea and wrote the manuscript. SM, SW, YK, KK, JM, KG: Verified the data.

Competing Interest: Authors declare that no conflict of interest exists regarding the writing of this article.

Ethical statement: This work did not violate ethical laws. As a result, no ethical approval required.

Grant Support Details: This work did not receive funding from any agency.

References:

1. Parry CM, Hien TT, Dougan G, White NJ, Farrar JJ. Typhoid fever. *N Engl J Med.* 2002 Nov 28;347(22):1770-82. doi: 10.1056/NEJMra020201. PMID: 12456854.

Cite this article as:

Murarkar K, Mankar S, Warthi S, Kapse Y, Kataria K, Moon J, et al. Young patient's chronic fever. *International Journal of Microbial Science* [Internet]. 2022;3(1). Available from: <http://dx.doi.org/10.55347/theijms.v3i1.1>

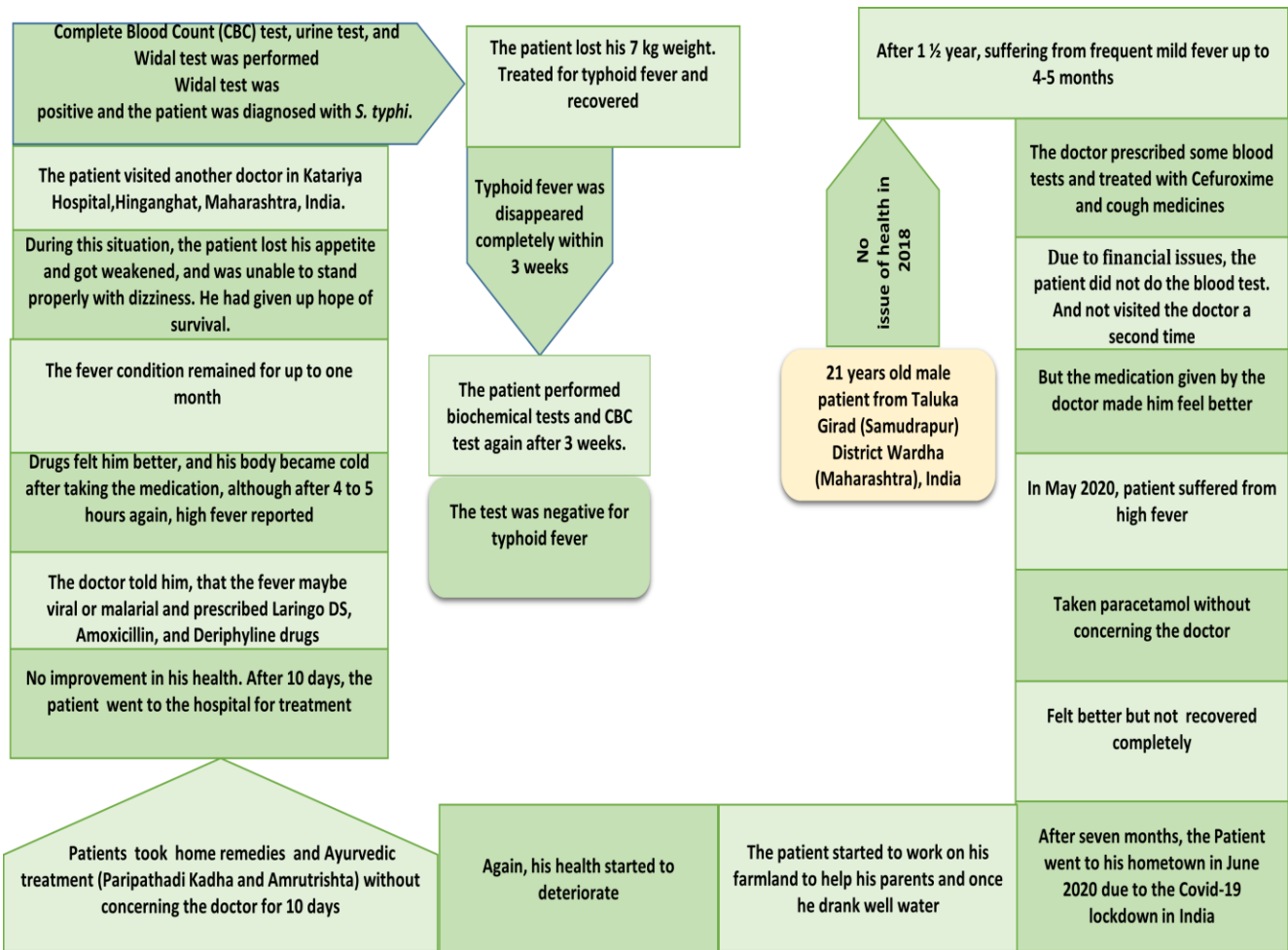


Figure 1: Events occurred in the life of young patient under study.

